

Meeting abstract

Open Access

1054 Noninvasive Qp/Qs ratio measurement with phase-contrast cine MRI in patients with atrial septal defect: comparison with heart catheterization

Amedeo Chiribiri*, Laura Rizzo, Maria Cristina Marocco, Marco Allasia, Rodolfo Bonamini, Fulvio Orzan, Cesare Fava and Gian Paolo Trevi

Address: University of Torino, Italy, Torino, Italy

* Corresponding author

from 11th Annual SCMR Scientific Sessions
Los Angeles, CA, USA. 1–3 February 2008

Published: 22 October 2008

Journal of Cardiovascular Magnetic Resonance 2008, **10**(Suppl 1):A179 doi:10.1186/1532-429X-10-S1-A179

This abstract is available from: <http://jcmr-online.com/content/10/S1/A179>

© 2008 Chiribiri et al; licensee BioMed Central Ltd.

Introduction

Blood flow can be quantified noninvasively by phase-contrast cine MRI (PC-MRI) in adults. Little is known about the accuracy of this measurement in patients with known atrial septal defect.

Purpose

Aim of the study was to compare the results of PC-Mri with heart catheterization

Methods

In 25 patients with a type-II atrial septal defect, blood flow rate in the great vessels was determined by 1 Tesla PC-MRI and the ratio of pulmonary to aortic flow (Qp/Qs) was compared with Qp/Qs by oximetry requiring heart catheterization, performed before of an attempt of percutaneous closure of the defect.

Results

The interval between measurements was 11 ± 18 days (range 1–78 days). Mean Qp was 9.2 ± 3.3 l/min with PC-MRI, and 8.6 ± 4 l/min with catheterization ($p = 0.57$). Mean Qs was 4.8 ± 1.6 l/min with PC-MRI, and 4.5 ± 1.3 l/min with catheterization ($p = 0.46$). Qp/Qs ratio was 1.99 ± 0.72 with PC-MRI, and 1.96 ± 0.96 with catheterization ($p = 0.92$).

The correlation analysis showed a good overlap between measurements (Qp: $r = 0.65$, $p = 0.0004$; Qs: $r = 0.64$, $p =$

0.0005 ; Qp/Qs ratio: $r = 0.68$, $p = 0.0002$), also confirmed by regression analysis ($R^2 = 0.42$, $p < 0.001$ for Qp; $R^2 = 0.41$, $p = 0.001$ for Qs; $R^2 = 0.46$, $p < 0.001$ for Qp/Qs ratio), and by the Bland-Altman statistical analysis for method comparison (see Figure 1). The interobserver variability was low.

Conclusion

Determination of Qp/Qs ratio by PC-MRI is quick, safe, and reliable compared with oximetry. This noninvasive method could be used to quantify the interatrial shunt in patients with known atrial septal type-II defect, in order to demonstrate hemodynamic importance of the defect, and to reduce the need for time-consuming diagnostic heart catheterization.

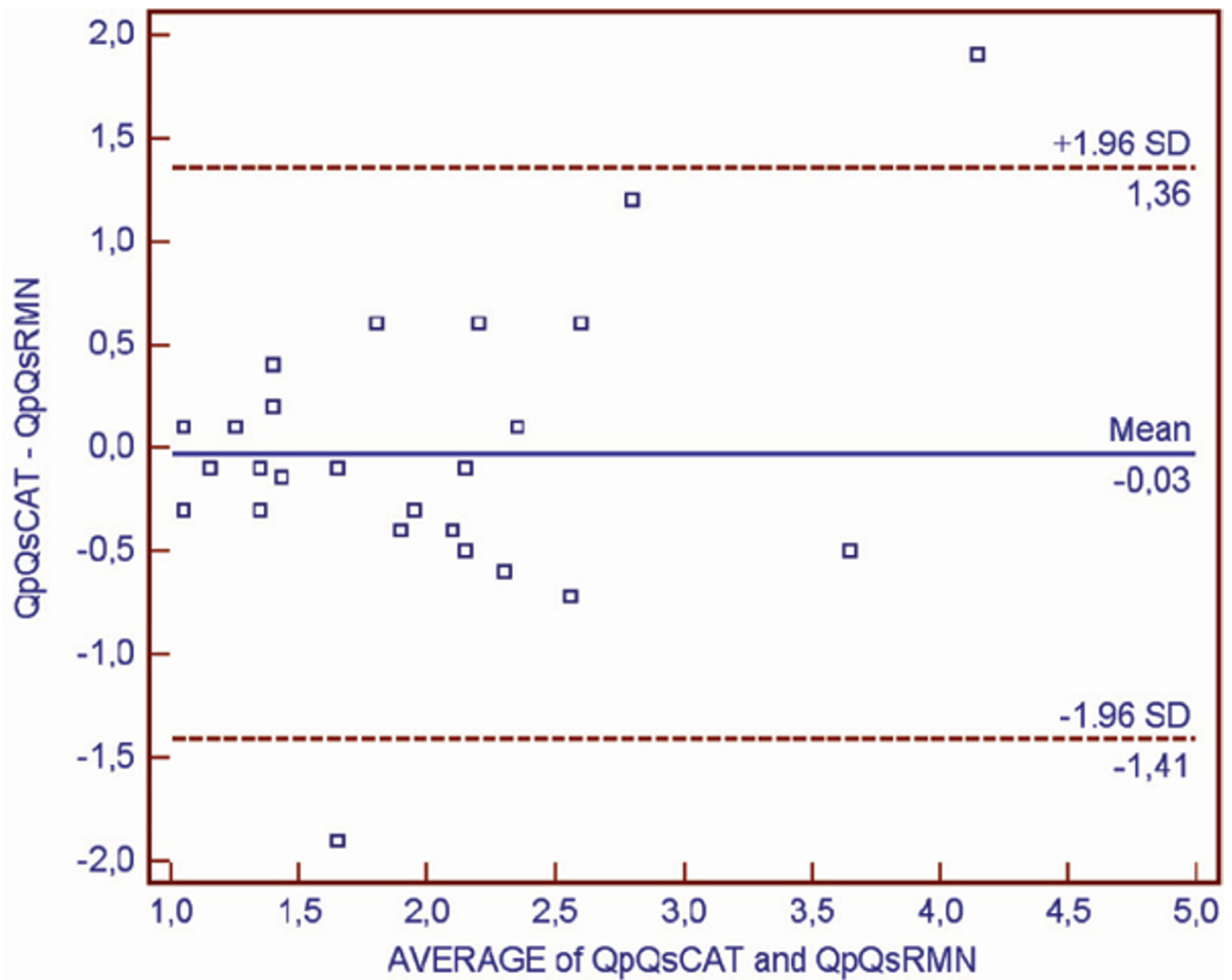


Figure 1

Publish with **BioMed Central** and every scientist can read your work free of charge

"BioMed Central will be the most significant development for disseminating the results of biomedical research in our lifetime."

Sir Paul Nurse, Cancer Research UK

Your research papers will be:

- available free of charge to the entire biomedical community
- peer reviewed and published immediately upon acceptance
- cited in PubMed and archived on PubMed Central
- yours — you keep the copyright

Submit your manuscript here:
http://www.biomedcentral.com/info/publishing_adv.asp

