

ORAL PRESENTATION

Open Access

Fuzzy-logic, manual and semi-automated 2SD-based approaches for quantification of myocardial necrosis from late contrast enhancement magnetic resonance images: comparison with biochemical assessment of infarct size and left ventricular volumes and function early after myocardial infarction

Nicolas Baron

From 2011 SCMR/Euro CMR Joint Scientific Sessions
Nice, France. 3-6 February 2011

Purpose

Cardiac Magnetic Resonance Imaging (CMR) provides reliable estimation of the extent of necrosis after acute myocardial infarction (AMI). Nevertheless usual quantification methods are time consuming and subjective. We sought to assess necrosis extent with a new method (fuzzy c-means clustering), compared to usual methods, applied on Late Gadolinium Enhancement (LGE) sequences. Results were compared to biochemical markers of necrosis and LV functional parameters.

Methods

CMR was performed 50±21 hours after AMI in 52 consecutive patients. We quantified the amount of necrosis using three approaches: 1) automated fuzzy c-means clustering method, 2) +2SD thresholding approach with manually defined remote myocardium, 3) +2SD thresholding approach with automated definition of the remote myocardium. Results were compared with

biochemical marker-estimated necrosis amount and left ventricular (LV) functional parameters.

Results

Although the 3 methods strongly correlated (r 0.89 to 0.99, $p < 0.0001$ for all), the quantified amount of necrosis was significantly different between methods. Manual quantification reported highest (20.5±17.6%), whereas fuzzy c-means clustering reported lowest (12.5±12.1 %) values. Strongest correlations were found between fuzzy c-means and both biochemical quantification of necrosis (r 0.61 to 0.80) and LV functional parameters (r 0.55 to 0.71).

Conclusions

The fuzzy c-means-assessed amount of necrosis on CMR images shows higher correlation with biochemical infarct size quantification as well as left ventricular global and regional function than usual methods. This method may be clinically useful in the evaluation of patients with AMI.

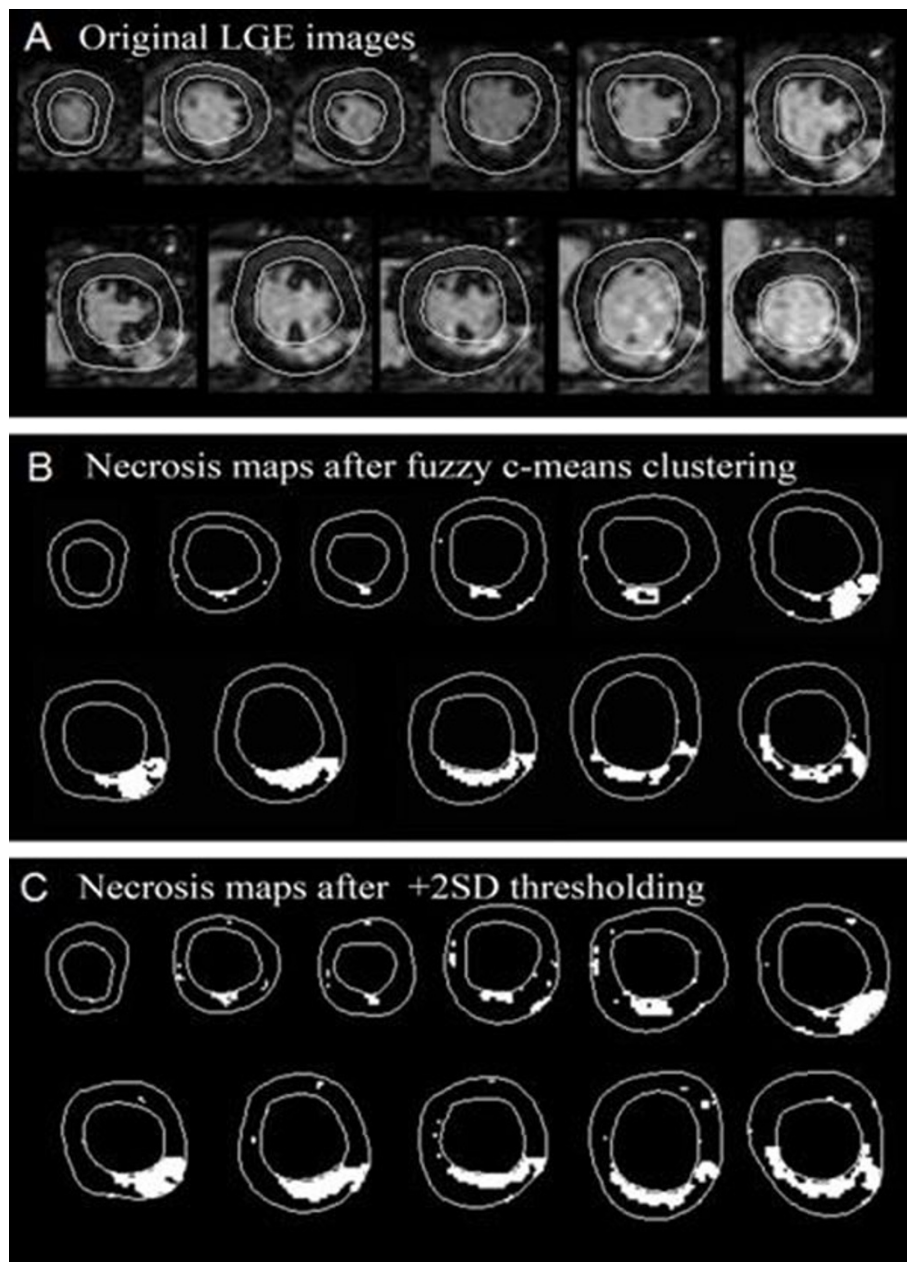


Figure 1

Published: 2 February 2011

doi:10.1186/1532-429X-13-S1-O106

Cite this article as: Baron: Fuzzy-logic, manual and semi-automated 2SD-based approaches for quantification of myocardial necrosis from late contrast enhancement magnetic resonance images: comparison with biochemical assessment of infarct size and left ventricular volumes and function early after myocardial infarction. *Journal of Cardiovascular Magnetic Resonance* 2011 13(Suppl 1):O106.

Submit your next manuscript to BioMed Central and take full advantage of:

- Convenient online submission
- Thorough peer review
- No space constraints or color figure charges
- Immediate publication on acceptance
- Inclusion in PubMed, CAS, Scopus and Google Scholar
- Research which is freely available for redistribution

Submit your manuscript at
www.biomedcentral.com/submit

 **BioMed Central**