

ORAL PRESENTATION

Open Access

# Severe aortic stenosis has blunted myocardial T1 relaxation response to vasodilator stress: a cardiac magnetic resonance adenosine stress test study

Masliza Mahmood<sup>1\*</sup>, Stefan K Piechnik<sup>1</sup>, Eylem Levelt<sup>1</sup>, Vanessa M Ferreira<sup>1</sup>, Jane M Francis<sup>1</sup>, Andrew Lewis<sup>1</sup>, Nikhil Pal<sup>1</sup>, Housman Ashrafian<sup>1</sup>, Stefan Neubauer<sup>1</sup>, Theodoros D Karamitsos<sup>1,2</sup>

From 18th Annual SCMR Scientific Sessions  
Nice, France. 4-7 February 2015

## Background

Aortic stenosis is characterized by impaired myocardial perfusion reserve due to coronary microvascular dysfunction. T1 mapping is sensitive to myocardial water content of both intra- and extracellular in origin, but the effect of intravascular compartment changes on T1 has never been assessed previously. We aimed to assess the effect of adenosine-induced vasodilatation on native (pre-contrast) T1 values in patients with severe aortic

stenosis (AS) before and after aortic valve replacement (AVR).

## Methods

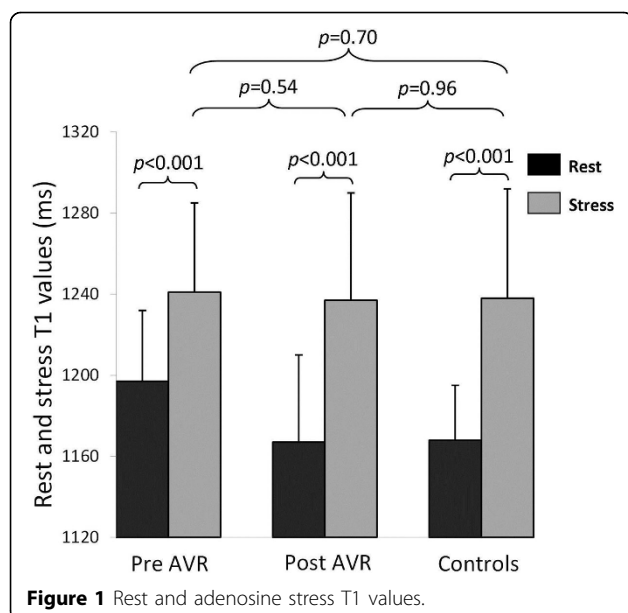
42 subjects (26 patients with severe AS without obstructive coronary artery disease and 16 controls) underwent cardiovascular magnetic resonance at 3T for native T1-mapping (ShMOLLI), first-pass perfusion (myocardial perfusion reserve index-MPRI) at rest and

**Table 1 Baseline clinical characteristics of severe AS patients and normal controls**

	Severe Aortic Stenosis (n = 26)	Normal controls (n = 16)	P value
Age (years)	67.8 ± 9	63.3 ± 3.4	0.06
Male, n (%)	19 (73)	8 (53)	0.16
Body mass index (kg/m <sup>2</sup> )	27.8 ± 4.5	27.0 ± 3.8	0.38
Systolic blood pressure (mmHg)	134.4 ± 18.1	131.0 ± 11.0	0.51
Diastolic blood pressure (mmHg)	74.4 ± 9.4	76.5 ± 10.2	0.51
Heart rate (bpm)	66.1 ± 9.4	64.3 ± 10.5	0.58
Peak AV gradient (mmHg)	83.1 ± 14.6	-	
CMR findings			
Aortic valve area (cm <sup>2</sup> )	0.82 ± 0.02	4.04 ± 0.75	<0.001
LV end-diastolic volume (ml)	143.2 ± 44.4	133.7 ± 33.1	0.47
LV ejection fraction (%)	74.5 ± 5.8	68.8 ± 6.4	0.005
LV mass index (g/m <sup>2</sup> )	96.0 ± 31.2	55.8 ± 13.9	<0.001
Presence of LGE, n (%)	21 (81)	0	<0.001
Myocardial T1 (ms)	1196 ± 47	1168 ± 27	0.037

Values are mean ± SD or percentages. CMR indicates cardiovascular magnetic resonance; LGE, late gadolinium enhancement; LV, left ventricular.

<sup>1</sup>Division of Cardiovascular Medicine, Radcliffe Department of Medicine, Oxford Centre for Clinical Magnetic Resonance Research, Oxford, UK  
Full list of author information is available at the end of the article



during adenosine stress, and late gadolinium enhancement (LGE).

## Results

AS patients had increased resting myocardial T1 ( $1196 \pm 47$  ms vs.  $1168 \pm 27$  ms,  $p=0.037$ ), reduced MPRI ( $0.92 \pm 0.31$  vs.  $1.74 \pm 0.32$ ,  $p<0.001$ ), and increased left ventricular mass index (LVMI) and LGE volume compared to controls (Table 1). T1 values had positive correlation with LVMI, LGE volume but an inverse correlation with aortic valve area and MPRI. During adenosine stress, the maximal T1 in AS was similar to controls ( $1240 \pm 51$  ms vs.  $1238 \pm 54$  ms,  $p=0.88$ ), possibly reflecting a similar level of maximal coronary vasodilatation in both groups (Figure 1). Interestingly, the T1 response to stress was blunted in AS ( $\Delta T1$   $3.7 \pm 2.7\%$  vs.  $6.0 \pm 4.2\%$  in controls,  $p=0.013$ ). Seven months after AVR ( $n=16$ ) myocardial T1 and response to adenosine stress recovered towards normal.

## Conclusions

Our findings suggest that intravascular compartment is a significant contributor to myocardial T1 relaxation time. Vasodilator stress T1 mapping may be a potential technique to assess coronary reserve without the need for contrast administration. Performing T1 mapping soon after vasodilator stress may affect ECV measurements given that hyperemia alone substantially alters T1 values.

## Funding

N/A.

## Authors' details

<sup>1</sup>Division of Cardiovascular Medicine, Radcliffe Department of Medicine, Oxford Centre for Clinical Magnetic Resonance Research, Oxford, UK. <sup>2</sup>1st Department of Cardiology, AHEPA Hospital, Aristotle University of Thessaloniki, Thessaloniki, 54636, Greece.

Published: 3 February 2015

doi:10.1186/1532-429X-17-S1-O28

**Cite this article as:** Mahmod et al.: Severe aortic stenosis has blunted myocardial T1 relaxation response to vasodilator stress: a cardiac magnetic resonance adenosine stress test study. *Journal of Cardiovascular Magnetic Resonance* 2015 **17**(Suppl 1):O28.

**Submit your next manuscript to BioMed Central and take full advantage of:**

- Convenient online submission
- Thorough peer review
- No space constraints or color figure charges
- Immediate publication on acceptance
- Inclusion in PubMed, CAS, Scopus and Google Scholar
- Research which is freely available for redistribution

Submit your manuscript at  
www.biomedcentral.com/submit

 **BioMed Central**