

WALKING POSTER PRESENTATION

Open Access

New insights in swine model of ventricular tachycardia using quantitative myocardial tissue characterization

Sébastien Roujol^{1*}, Tamer A Basha¹, Cory M Tschabrunn¹, Kraig V Kissinger¹, Mark E Josephson¹, Warren J Manning^{1,2}, Elad Anter¹, Reza Nezafat¹

From 18th Annual SCMR Scientific Sessions
Nice, France. 4-7 February 2015

Background

Ventricular tachycardia (VT) is often responsible for sudden cardiac death and is generally triggered by the presence of reentry circuits related to a chronic myocardial scar. We have recently developed a novel swine model of VT, where sustained monomorphic reentrant VT can be induced in all animals. This new model offers exciting opportunities for better understanding the underlying substrate of VT, as well as for the development of new mapping and ablation strategies. In this study, we sought to provide in-vivo tissue characterization of this model using myocardial tissue characterization techniques of T_1 , T_2 and high-resolution LGE.

Methods

A novel swine model of reentrant VT was induced in 11 Yorkshire swine by 180 min balloon occlusion of the mid left anterior coronary artery. Each animal underwent an in-vivo CMR exam using a 1.5 T Philips scanner at 52 ± 13 days after infarction, followed by an electrophysiology study with programmed stimulation to assess for VT inducibility. During imaging, each animal was sedated, intubated and mechanically ventilated. Native T_1 mapping using MOLLI (1) and T_2 mapping (2) were performed and followed by bolus injection of 0.2 mmol/kg of gadobenate dimeglumine and post-contrast T_1 mapping using MOLLI. All these parametric sequences used ECG-triggered single shot acquisitions with balanced-SSFP imaging readout and the following parameters: (TR/TE=4.3/2.1ms, flip angle=35°(T_1 mapping)/85°(T_2 mapping), FOV=360×276 mm², voxel size=2×2 mm²,

slice thickness=8 mm, 10 slices (T_1 mapping)/5 slices(T_2 mapping), SENSE factor=2). Finally, high resolution LGE (3) was performed using a free breathing navigator-gated inversion recovery gradient echo sequence with the following parameters (TR/TE/ α =6.5/3.0ms/25°, FOV=270×270×112 mm³, voxel size=1×1×1 mm³, compressed sensing factor=4). All imaging was performed in the short axis orientation. Analysis was performed offline using an in-house platform. The areas of enhancement in LGE data was used to visually guide a manual segmentation of the corresponding areas in all T_1 and T_2 maps. A similar approach was used to delineate an area of healthy myocardium all T_1 and T_2 maps. T_1/T_2 maps with artifacts were discarded from the analysis. Native T_1 times and T_2 times are reported for both “remote area” and “area of enhancement”.

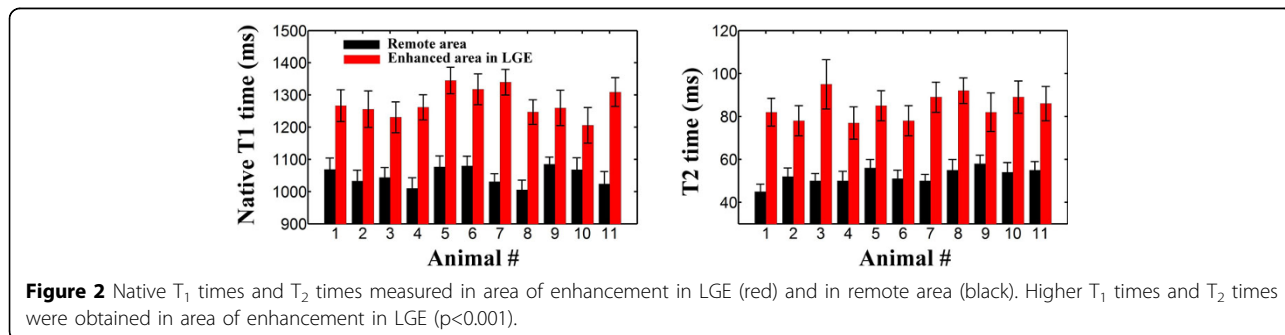
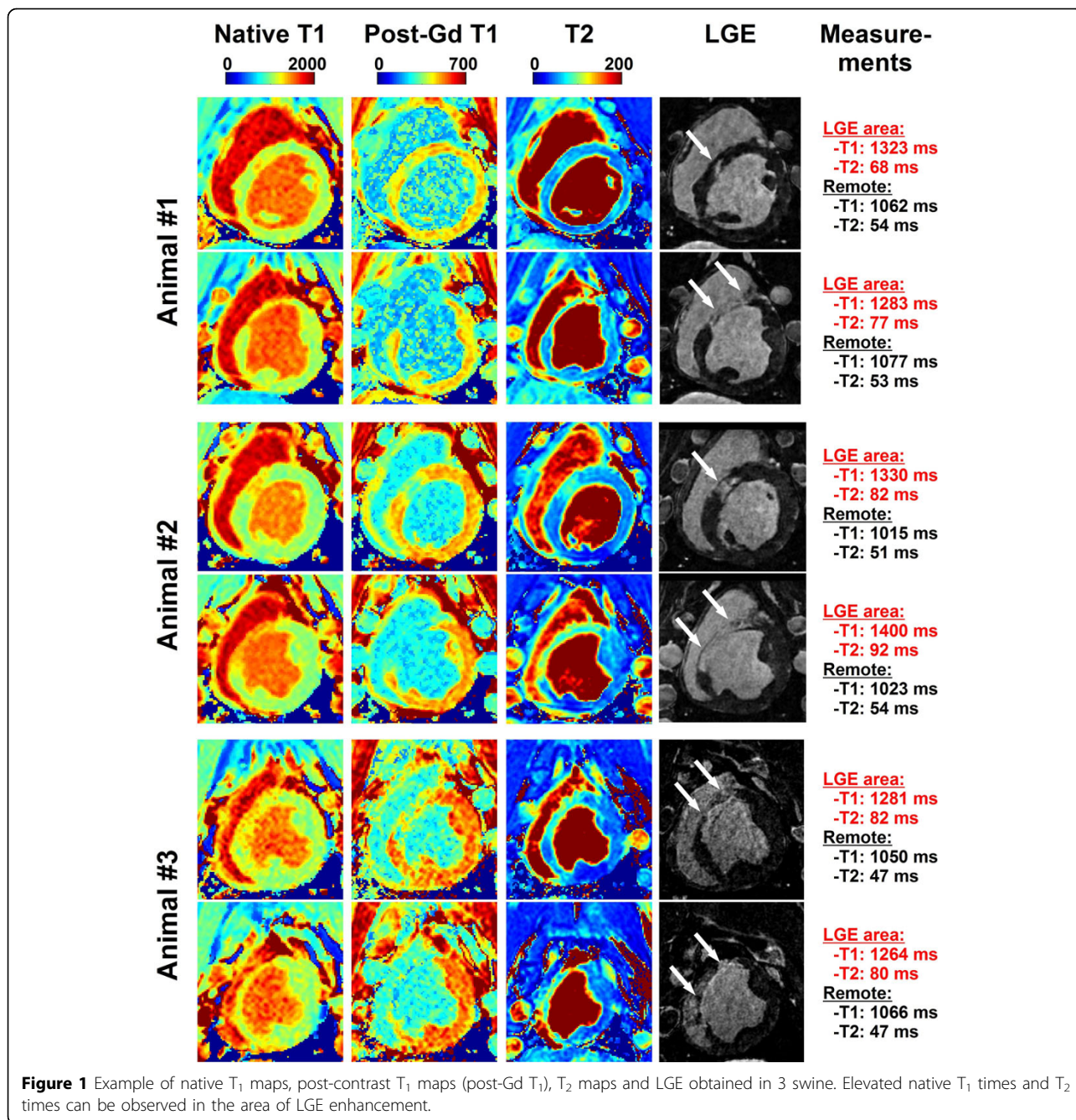
Results

Sustained reentrant VT could be induced in all animals. In-vivo CMR revealed that areas with elevated native T_1 times and T_2 times were in good agreement with areas depicting reduced post-contrast T_1 times and enhancement in LGE (Figure 1). Over all animals, area with enhancement as defined by LGE had higher native T_1 times (1276±45 vs. 1047±29, $p < 0.001$) and higher T_2 times (85±6 vs. 52±4, $p < 0.001$) than remote area (Figure 2).

Conclusions

In this swine model of reentrant VT, areas of LGE hyperenhancement are associated with elevated native T_1 times and T_2 times.

¹Department of Medicine, BIDMC / Harvard Medical School, Boston, MA, USA
Full list of author information is available at the end of the article



Authors' details

¹Department of Medicine, BIDMC / Harvard Medical School, Boston, MA, USA. ²Radiology, BIDMC / Harvard Medical School, Boston, MA, USA.

Published: 3 February 2015

References

1. Messroghli : *MRM* 2004.
2. Akçakaya : *MRM* 2014.
3. Akçakaya : *Radiology* 2014.

doi:10.1186/1532-429X-17-S1-Q132

Cite this article as: Roujol *et al.*: New insights in swine model of ventricular tachycardia using quantitative myocardial tissue characterization. *Journal of Cardiovascular Magnetic Resonance* 2015 17 (Suppl 1):Q132.

**Submit your next manuscript to BioMed Central
and take full advantage of:**

- Convenient online submission
- Thorough peer review
- No space constraints or color figure charges
- Immediate publication on acceptance
- Inclusion in PubMed, CAS, Scopus and Google Scholar
- Research which is freely available for redistribution

Submit your manuscript at
www.biomedcentral.com/submit

